DISEASES OF THE ORAL CAVITY, SALIVARY GLANDS, AND ESOPHAGUS

Dr.omnia salim

ILOS

- **Inflammatory lesions of the oral cavity**
- **Tumors of the lips** (including squamous cell carcinoma)
- Ulcers, precancerous lesions, and **tumors of the tongue**
- Causes of **parotid gland enlargement**
- **Salivary gland tumors**: mixed tumor & mucoepidermoid carcinoma
- **GERD, Barrett's esophagus**, and **esophageal tumors**

DISEASES OF THE LIPS

- **Herpes Simplex**
- Viral disease with fevers
- Vesicles on mucocutaneous junction of lips, buccal mucosa, conjunctiva
- Contain clear serous fluid + few leukocytes

TUMORS OF THE LIPS

- **1. Benign Tumors:**
- Squamous cell papilloma
- Salivary gland adenomas
- Fibroma
- Lipoma
- Hemangioma and lymphangioma

2. Malignant Tumors:

- **Squamous cell carcinoma**
- **Basal cell carcinoma**
- Malignant salivary gland tumors
- Angiosarcoma

SQUAMOUS CELL CARCINOMA

- A common tumor occurring more in males.
- It is more common in the lower lip.
- **Gross picture:**
- Usually a malignant ulcer with raised everted edges; less commonly a
- polypoid growth.
- **Microscopic picture:**
- Well and moderately differentiated squamous cell carcinoma.
- **Spread:**
  - Local infiltration of the chin and mandible.
  - Lymphatic spread to the submental and upper cervical lymph nodes.

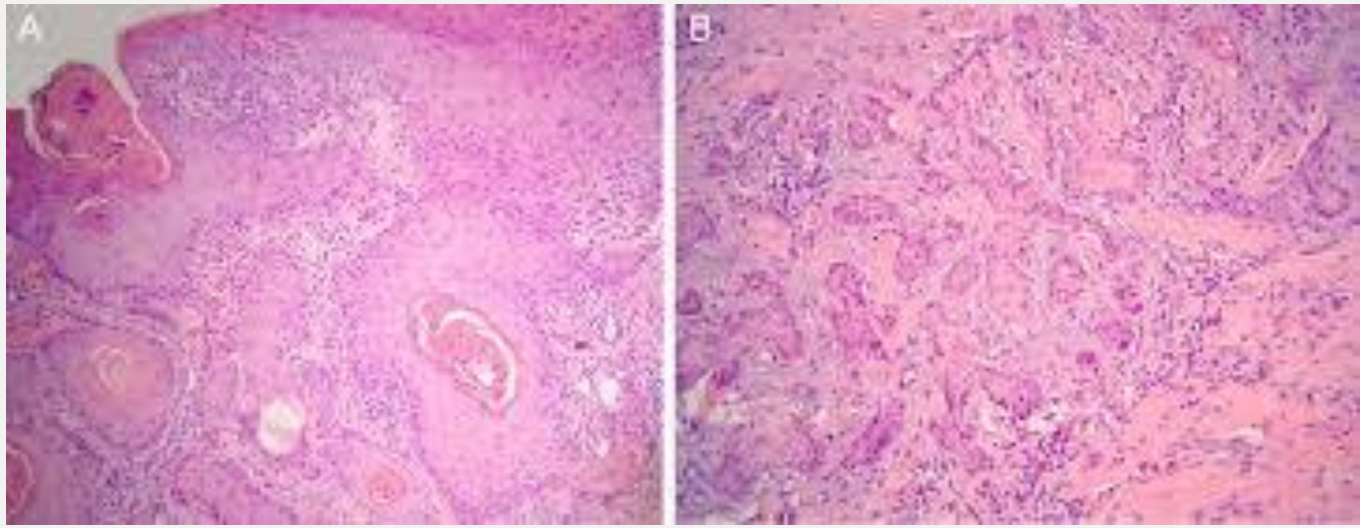

DISEASES OF THE MOUTH

1.Stomatitis

Catarrhal stomatitis

Aphthous Stomatitis

Herpetic Stomatitis

A granulocytic Angina

Vincent's Angina

2.Moniliasis or Thrush (Oral Candidiasis)

- **1.Stomatitis:**
- **Definition:** Inflammation of the mucous membrane of the oral cavity.
- **Catarrhal stomatitis**
- **Causes:** Hot and spicy food, excessive smoking, lack of oral hygiene, and in the course of infectious fevers.
- **Pathology:** The mucosa is congested and may show vesicles or superficial ulcers.
- **Aphthous Stomatitis**
- Allergic inflammation in children. The lesion appears as small **vesicles surrounded by red borders**. Rupture of the vesicles results in small ulcers with a grey floor which heal rapidly.
- **Herpetic Stomatitis**
- An acute disease occurring in **infants and young children**. It is the most common manifestation of primary infection with **herpes simplex virus**.
- The lesions are in the form of vesicles around the lips.

Aphthous Stomatitis

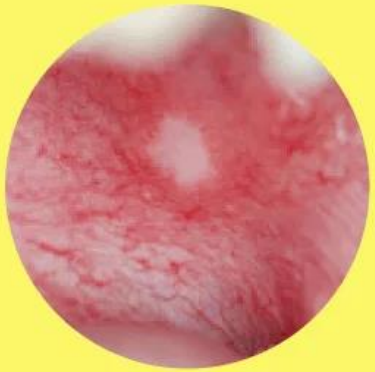

Herpetic Mucosal Inflammation

Candidal stomatitis

Types of stomatitis

MED DEO
Private medical clinic

- **Vincent's Angina**
- Necrotizing inflammation of the mucosa of tonsils and gums.
- It is caused by *Treponema vincenti* and *Bacillus fusiformis*

in patients with low resistance.

Separation of the mucosa leaves superficial or deep ulcers.

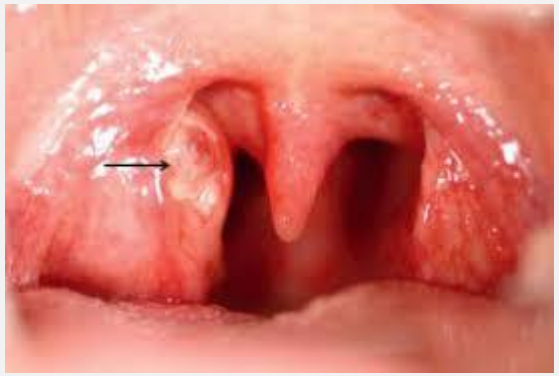

- **A granulocytic Angina**
- Severe inflammation of the gums and nasopharynx
- due to agranulocytosis (an acute condition in which

the absolute neutrophil count is decreased).

- The mucosa shows ulceration and necrosis.

2.MONILIASIS OR THRUSH (ORAL CANDIDIASIS)

- Infection by the fungus *Monilia albicans*.
- The fungus is found in the mouth, intestine, and vagina in healthy persons.
- Lesions develop in persons with low body resistance, in debilitating diseases, and with prolonged use of broad-spectrum antibiotics.

DISEASES OF THE TONGUE

- Diseases of the Tongue:
- Glossitis
- Leukoplakia
- Ulcers of the Tongue:
- Dental ulcer
- Dyspeptic ulcers
- Tuberculous ulcer
- Syphilitic ulcers –
- Malignant ulcer
- Tumors of the Tongue:
- Benign Tumors
- Malignant Tumors

- **Glossitis**
- **Definition:** Inflammation of the tongue
- **Types:**
- **Acute Glossitis:**
  - **Acute superficial glossitis:** A part of catarrhal stomatitis.
  - **Acute parenchymatous glossitis:** Deep inflammation affecting the muscles of the tongue, complicating deep wounds of the tongue.
- **Chronic Glossitis:**
  - **Chronic superficial glossitis:** Caused by
  - chronic irritation due to excessive smoking, a ragged tooth, or syphilitic inflammation. Early on, the mucosa shows hyperemic patches; later, leukoplakia occurs.
  - **Chronic glossitis of malnutrition:** Caused by deficiency of vitamin B complex and iron.

LEUKOPLAKIA

- **Definition:** thick, white mucosal patches that cannot be scraped off.
  Cause: Chronic irritation due to
- excessive smoking, a ragged tooth,
- or diffuse syphilitic inflammation **(tertiary).**
  Gross picture: White, thick patches with sharp outlines.
- The lesion may also affect the buccal mucosa.
- **Microscopically:**
- **Squamous cell hyperplasia, can develop into dysplasia,**
- carcinoma *in situ*, and invasive carcinoma.
- The stratified squamous epithelium shows :
- **acanthosis** (hyperplasia of the prickle cell layer)
- **and hyperkeratosis** (increased thickness of the superficial
- keratinized layer).
- The submucosa shows chronic inflammation and fibrosis.
- It can also be seen in inflammatory conditions unrelated to
- malignancy and in immunocompromised patients.

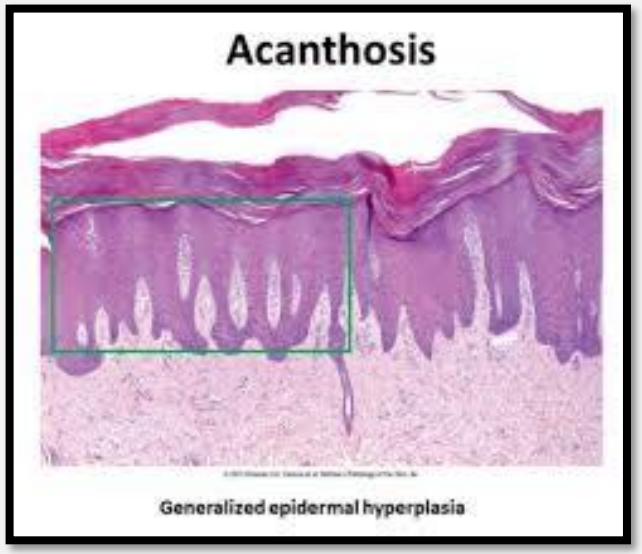

ULCERS OF THE TONGUE

- **Dental ulcer:** Traumatic ulcer at the edge of the tongue

related to a sharp tooth.

Dyspeptic ulcers:

Multiple, small, superficial, painful ulcers

of short duration.

Tuberculous ulcer:

Undermined ulcer near the tip caused by

coughed sputum in cases of open pulmonary tuberculosis.

- **Syphilitic ulcers:** Either a chancre, mucous patches which ulcerate, or a gumma which ulcerates.
- The ulcer is found on the dorsum. The edges are punched out, and the base is indurated.
- a chancre

a gumma

- **Malignant ulcer:** Common in the anterior two-thirds.
- The edges are **raised** and **everted**, the floor is necrotic,
- and the base is indurated.

Tongue ulcers

Dental

Apthous

T.B.

Malignancy

TUMORS OF THE TONGUE

- **Benign Tumors:** Squamous **cell papilloma**, cavernous **hemangioma**, cavernous **lymphangioma**, fibroma, leiomyoma, myoblastoma.
- **Malignant Tumors:** Squamous cell carcinoma, adenocarcinoma.
- **Squamous Cell Carcinoma :**More common in middle-aged males.
- **Precancerous lesions:**
  - Leukoplakia
  - Tertiary syphilis of the tongue
  - Squamous cell papilloma

- **Gross picture:** More common in the anterior two-thirds.
- Commonly a malignant ulcer with everted edges.
- **Microscopic picture:** Squamous cell carcinoma with all grades of differentiation.

DISEASES OF THE SALIVARY GLANDS

Causes of Parotid Enlargement

(a)Suppurative parotitis

(b) Mumps (epidemic parotitis)

(c) Mickulicz disease

(d) Parotid calculi

(e) Parotid tumors

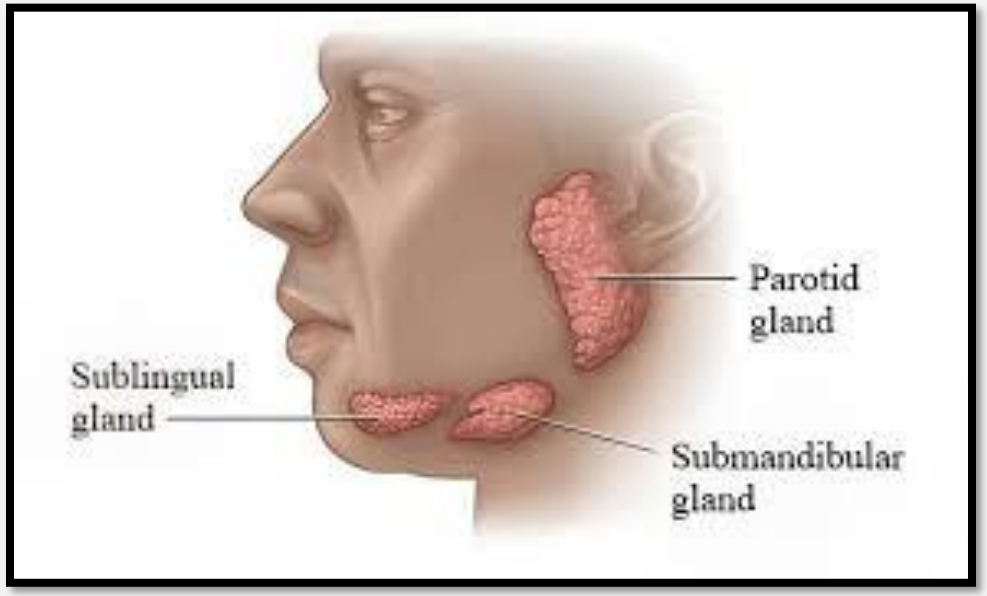

MUMPS (EPIDEMIC PAROTITIS)

- **Definition:** A systemic viral infection in children mainly affecting the parotid glands. Infection is by the droplet method.
  Pathology: Non-suppurative inflammation of both parotid glands.
- The interstitial tissue is congested and infiltrated by lymphocytes and macrophages. Fibrosis may follow.
  Complications (rare):
- Orchitis, specially in adults (may lead to fibrosis & sterility).
- Oophoritis, pancreatitis, mastitis, and meningoencephalitis.

TUMORS OF SALIVARY GLANDS

- **Benign Tumors:**
  - **Pleomorphic adenoma (benign mixed salivary gland tumor)**
  - Monomorphic adenoma
  - Adenolymphoma

Malignant Tumors:

- Malignant mixed salivary gland tumor
- **Mucoepidermoid carcinoma**
- Adenoid cystic carcinoma
- Acinic cell tumor

PLEOMORPHIC ADENOMA (BENIGN MIXED SALIVARY TUMOR)

- The commonest benign tumor of the salivary glands, usually affecting the parotid gland (90%).
- It is more common in females.
- **Gross picture:**
  - A slowly growing, **capsulated tumor (incomplete capsule)**
  - arising from the lower part of the parotid gland.
  - Forms a **round or oval lobulated** mass 2-5 cm in diameter,
  - **firm and rubbery**.
  - The cut surface is **grayish-white with soft areas**, **blue translucent** chondroid areas,
  - cystic areas with **myxomatous tissue(cartilage ,bone),** cystic areas with clear fluid

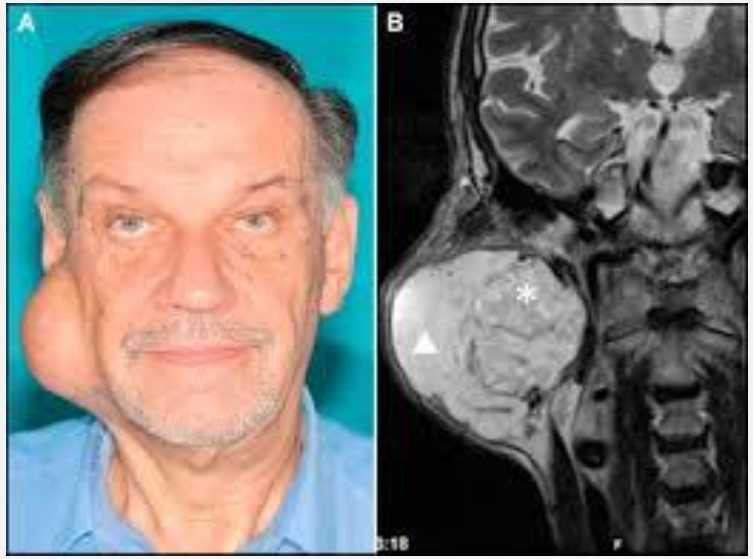

- **Microscopic picture:** A heterogenous structure of:
  - (a) Epithelial elements:
  - Form ducts, acini, tubules, and sheets of cells of ductal and myoepithelial origin.
  - (b) Mesenchymal elements:
  - Loose connective tissue, myxoid tissue, chondroid matrix, and rarely bone.
- Behavior: Slow rate of growth. Recurrence after surgical removal may occur. The tumor may undergo malignant change.

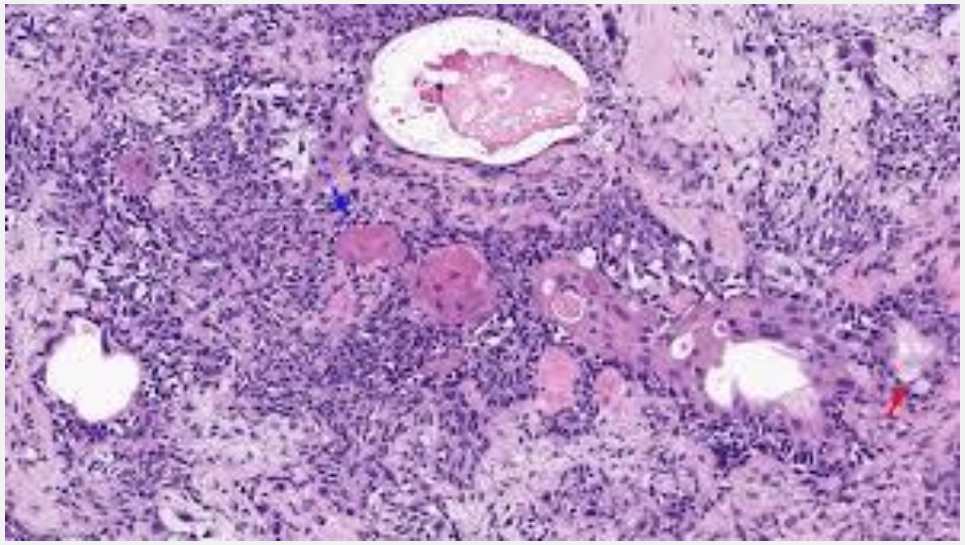

- **(a) Epithelial elements**
- **Form ducts, acini, tubules,**
- **and**
- **sheets (cords 2 layers)**
- **(b)Myoepithelial cells**
- **in form of:**
- **Strands or clumps**
- **(c) Mesenchymal elements:**
- **Loose connective tissue,**
- **myxoid tissue,**
- **chondroid matrix,**
- **and rarely bone**

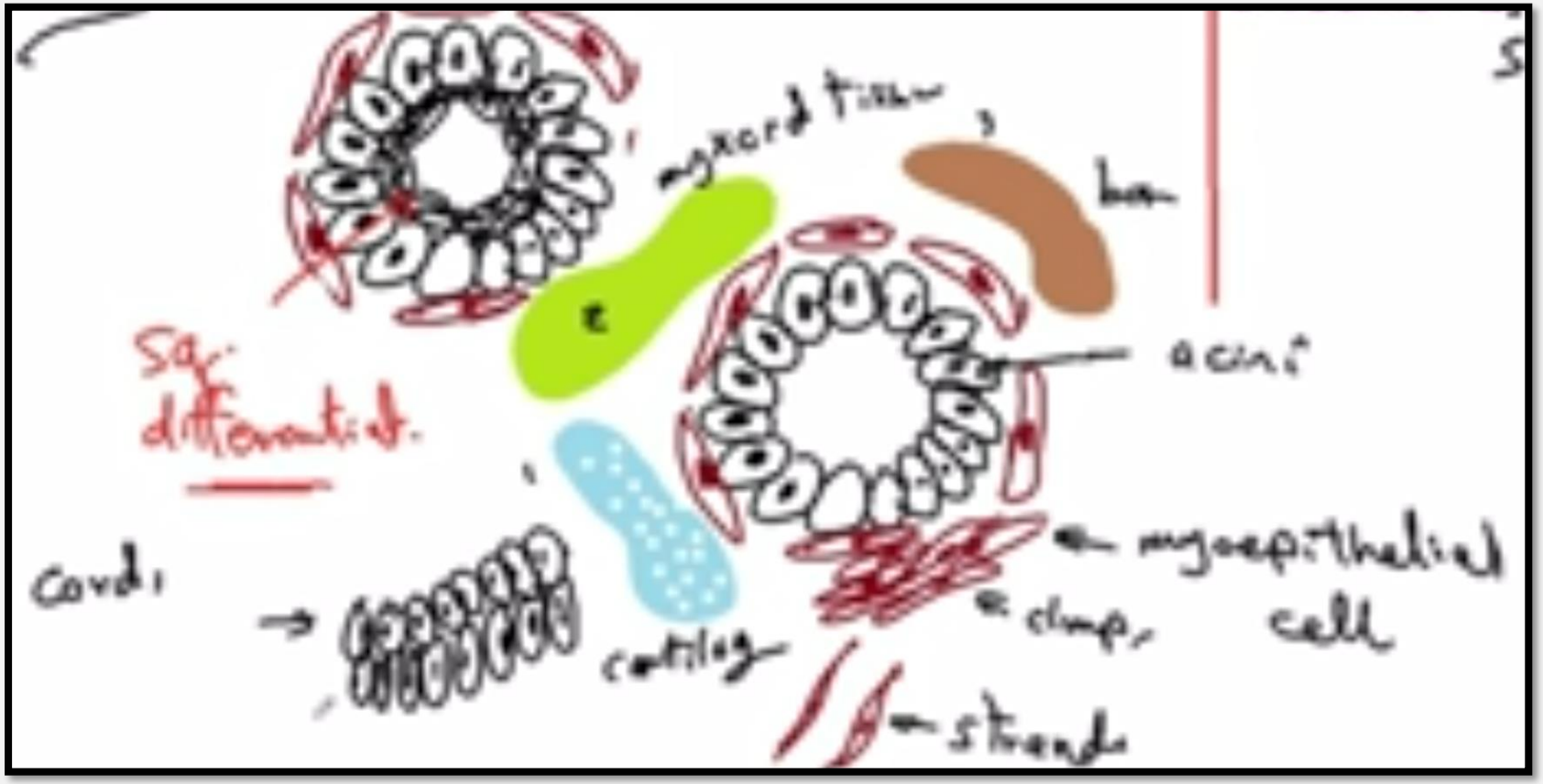

WARTHIN'S TUMOR (PAPILLARY CYSTADENOMA LYMPHOMATOSUM; ADENOLYMPHOMA)

- Almost always arises in the parotid glands. 2nd most common parotid tumor
- About 10% are bilateral and multifocal.
- common in male smokers after the age of 50.
- **Gross picture:**
- Round or oval capsulated tumor.
- **The cut surface shows:**
- cystic spaces with papillary projections
- containing mucinous gray or pale brown secretion.

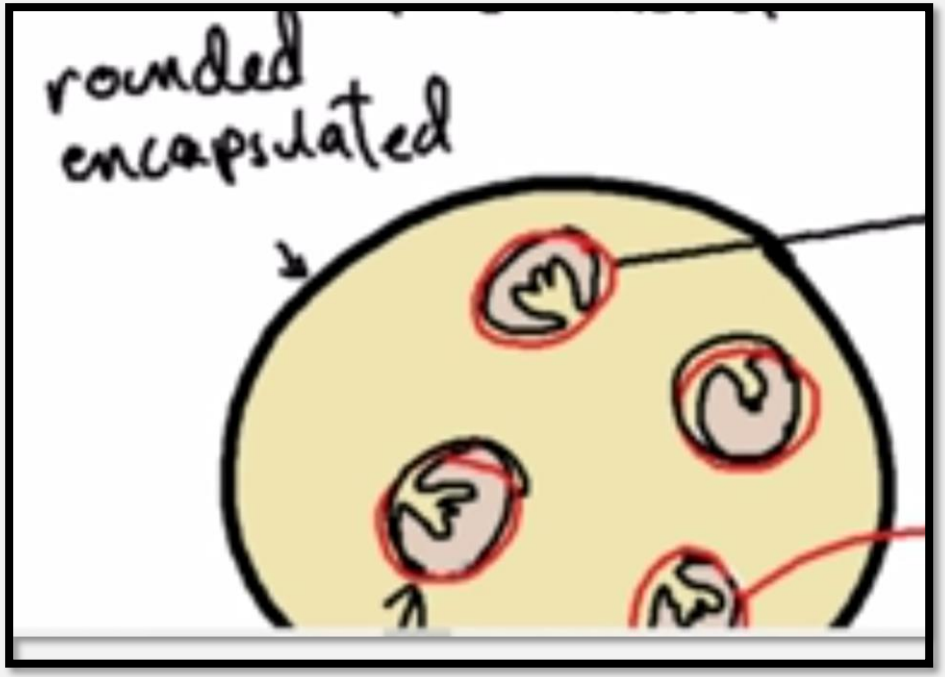

- **Microscopic picture:**
- Cystic spaces with mucin
- **the papillary projections contain 2 layers**
- Outer layer **cuboidal**
- Inner layer **columnar** contain granular cytoplasm
- Between columnar cells secretory cells give mucin
- Lymphocyte with germinal center

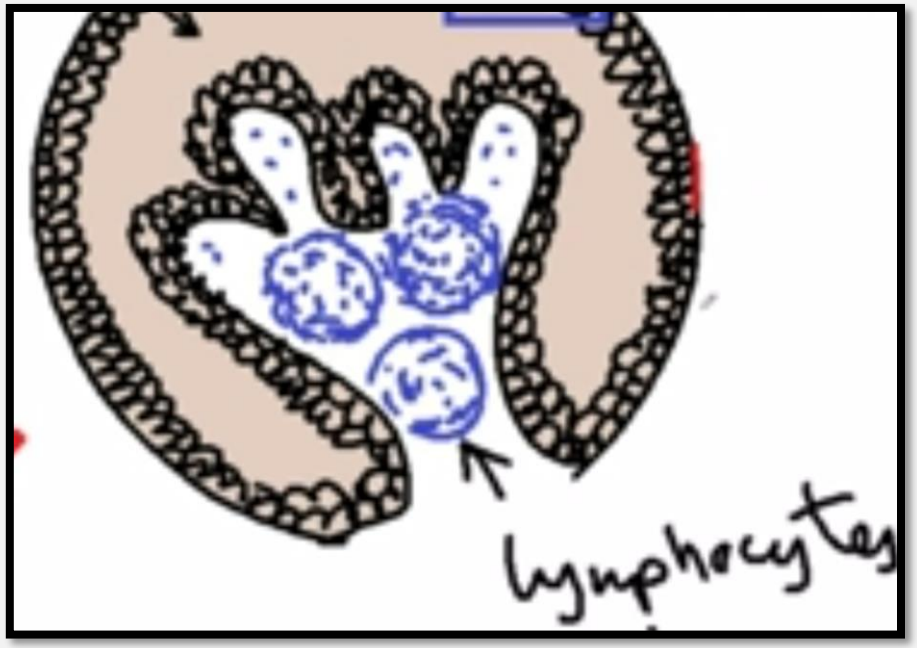

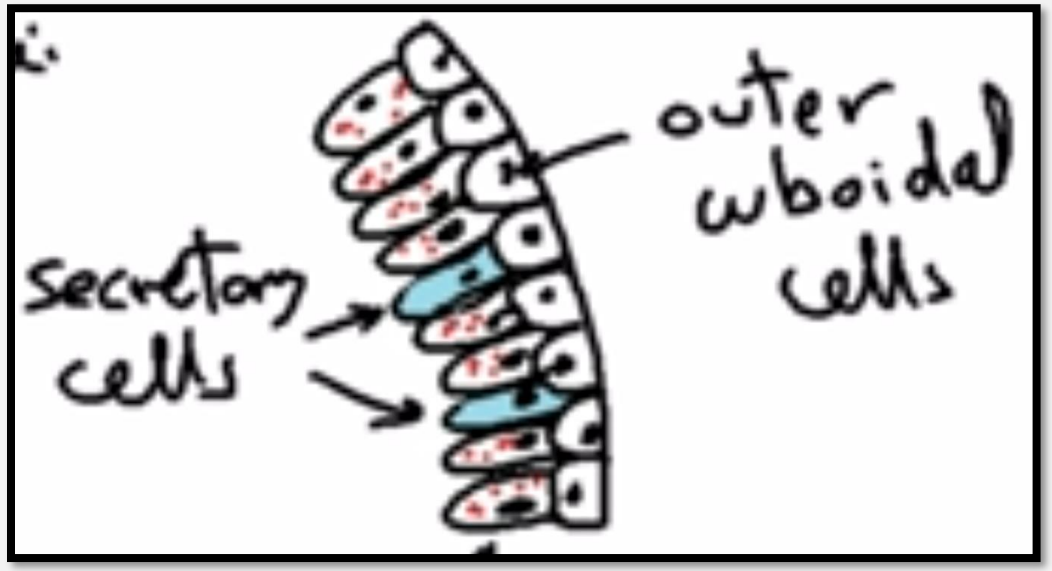

MUCOEPIDERMOID CARCINOMA

- Commonly affects the parotid. The tumor consists of three types of cells:
- **squamous cells, mucus-secreting cells, and intermediate cells. T**
- he cells form cords, sheets, or cystic spaces. According to cellular anaplasia, the tumor is either well, moderately, or poorly differentiated. Metastasis affects the regional nodes, lung, bone, and brain.
- **Grossly:** Usually circumscribed but not encapsulated, varying in size from 1 to 4 cm.
- **Microscopically:** Composed of a combination of 3 types of cells: mucin-producing,
- squamous, and intermediate cells. Well-differentiated tumors
- have a predominance of mucinous cells,
- while poorly differentiated have a more solid and infiltrative pattern.

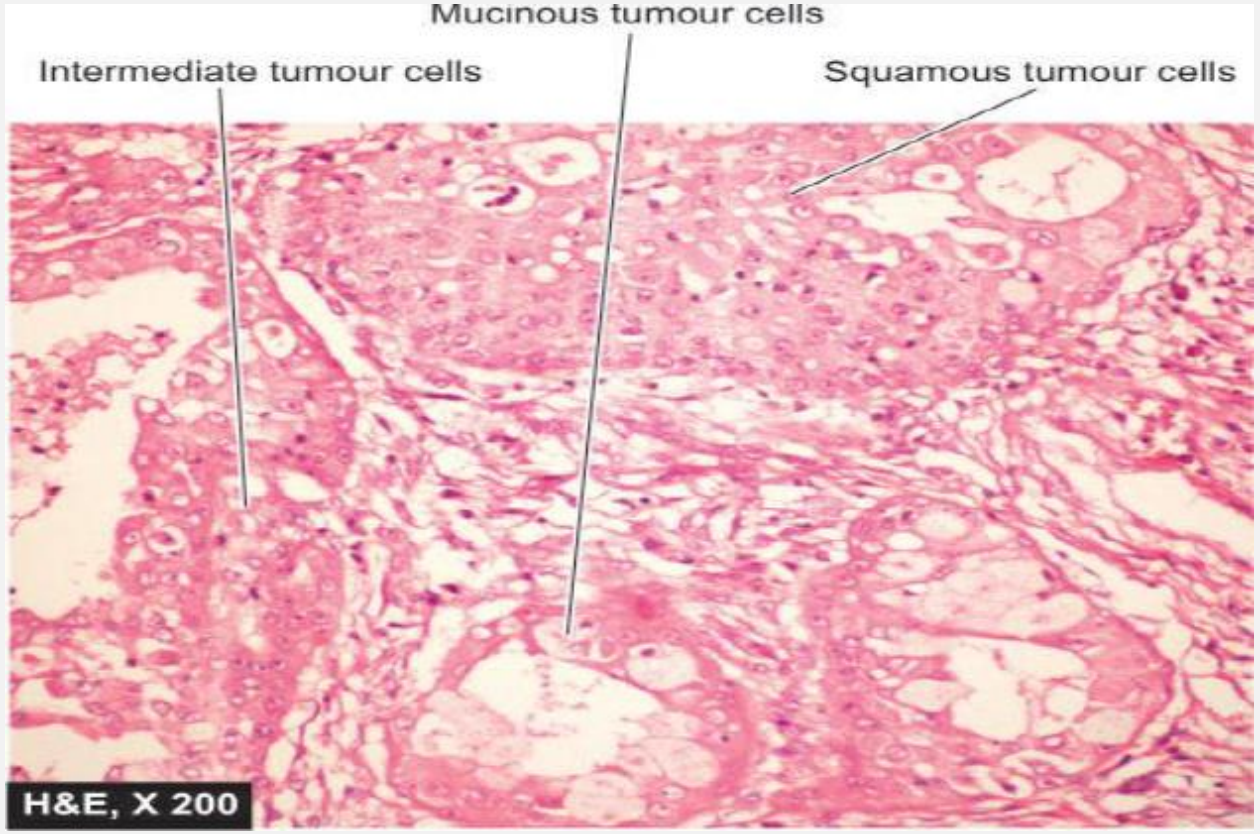
Mucinous tumour cells
Intermediate tumour cells
Squamous tumour cells
H&E, X 200

DISEASES OF THE ESOPHAGUS

- **Barrett Esophagus**
- **Definition:** A condition in which the stratified squamous epithelium

of the lower esophagus is replaced by columnar epithelium (columnar metaplasia) following reflux esophagitis.

- The mucosa appears velvety red.
- **Danger:**
- 30-100x risk of adenocarcinoma.

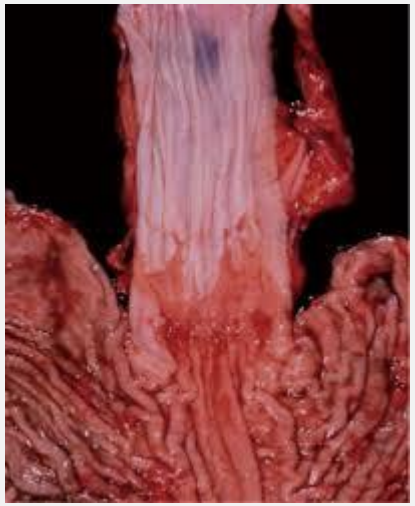

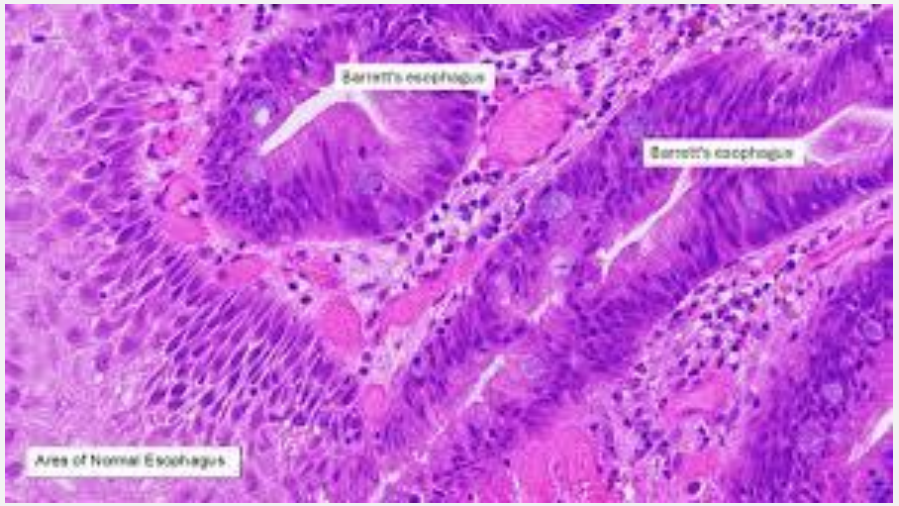

CARCINOMA OF THE ESOPHAGUS

- **Incidence:** More common in males of middle and old age. More common in the Black race, Far East, and Iran.
- **Risk factors:** Smoking, alcohol, achalasia, vitamin A, B, and C deficiency, HPV type 16 & 18, long-standing esophagitis, and genetic (racial) predisposition.
- **Site:** Upper esophagus (20%), middle (50%), lower (30%).
- **Macroscopic features:** Exophytic polypoid (60%),

circumferential (annular), ulcerating, or diffusely infiltrative tumor.

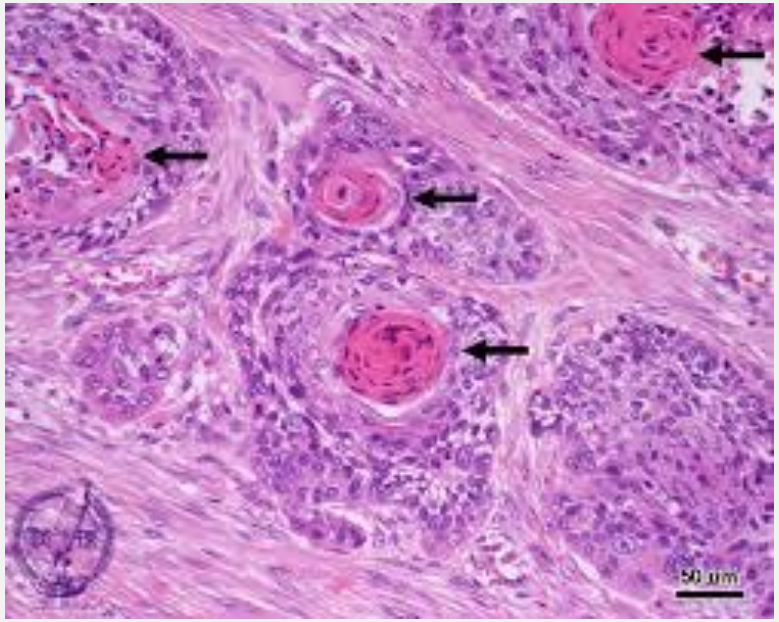

- Range from well to poorly differentiated squamous cell carcinoma (95%).
- The remainder is adenocarcinoma arising near the cardia,
- and others are undifferentiated.
- **Spread:**
  - **Local infiltration:** Of the mediastinal structures.
  - **Lymphatic spread:** To the supraclavicular, mediastinal, or coeliac groups of lymph nodes according to the site of the primary tumor.
- **Blood spread:** Lately to the lung and liver

ESOPHAGEAL VARICES

- **Definition:** Dilated, elongated, and tortuous veins in the submucosa of the lower end of the esophagus.
  Etiology: Liver cirrhosis, bilharzial hepatic fibrosis, portal vein obstruction by thrombosis or malignant infiltration.

Ulcers of the Esophagus

- **Types and causes:** Malignant ulcer, peptic ulcer, traumatic ulcer, corrosive ulcer, tuberculous ulcer.
  Effects: Hematemesis, fibrous stricture.